

Chapter 17

DYSBARIC OSTEONECROSIS

**(DIVERS BONE DISEASE,
AVASCULAR NECROSIS OF BONE,
ASEPTIC BONE NECROSIS,
BONE NECROSIS, BONE ROT,
CAISSON DISEASE OF BONE)**

This was first noticed in caisson (tunnel) workers in the 19th century, and was described as being an area of localised bone death, predominantly occurring in the long bones of the arms and thighs.

If this area of dead bone is located beneath the joint surface of the bones in the hip or shoulder joints, pain and symptoms of arthritis, along with a reduction in mobility of the joint is a common consequence – often occurring in mid or later life.

The exact cause of the disorder is probably a delayed effect of damage caused by gas bubbles produced during a dive (see Chapter 13). In this sense it is a delayed form of decompression sickness.

Cause

Bone is a living organ containing bone cells which constantly absorb and lay down new bone. It has a cleverly designed structure which resembles reinforced concrete or fibreglass and contains fibres of a sinew-like substance called collagen, embedded in a concrete-like calcium material. This is traversed by numerous vessels which supply the blood to the bone cells embedded in the bone. The bone cells permit the repair of fractures and allow the bone to change its structure to accommodate stresses which may vary during the person's life.

If the blood vessels supplying the bone cells are blocked by gas bubbles or any other cause, the bone cells die and the self-repairing ability of the bone stops. It becomes unable to fix the

repeated minor trauma which is common around joints and eventually the bone structure collapses causing permanent damage to the major load bearing joints, such as the hips or shoulders.

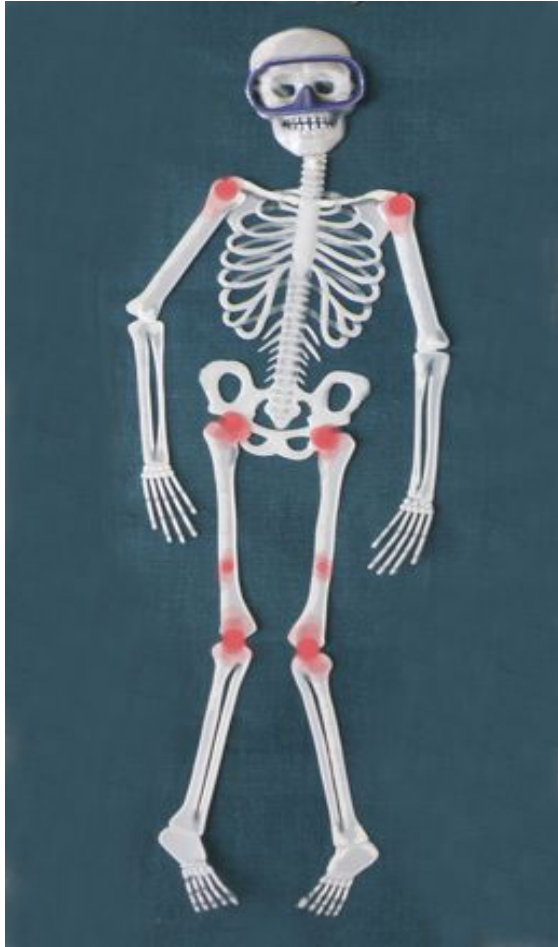


Fig. 17.1

The reported incidence of this condition varies from less than 1% in some Navy series, to 80% in Chinese commercial divers. This variance is probably due to factors such as different diagnostic criteria and differing ages, dive patterns, deco procedures and dive frequency.

Predisposing factors which are commonly associated with osteonecrosis include:

- **age greater than 30 years**
- **inadequate decompressions**
- **experimental dives**
- **deep dives**
- **decompression sickness**
- **long duration dives**

X-Ray changes have been seen as soon as 3 months after a dive and it has been reported following a single dive to 30 metres. When joint involvement does occur, the onset of symptoms is usually delayed for many years, reflecting the time required for joint destruction. Fortunately, in most cases the disease does not cause any serious damage to the joints and so produces no symptoms.

Occasionally bone pain may increase during recompression treatment, or may persist after treatment. Some of these progress to dysbaric osteonecrosis over the following months.

Classification of Bone Necrosis

The lesions are classified into two groups:

- **Type A lesions** – which are near the joint surface (juxta-articular).
- **Type B lesions** – which are remote from the joint surface (head, neck and shaft).

□ **Type A lesions.**

With these, the joints may become involved as the under-lying bone is destroyed and the joint surface collapses. This may produce symptoms which are potentially crippling. Hips and shoulders are more frequently affected.

□ **Type B lesions.**

These rarely cause symptoms and are generally of little clinical importance, except to suggest more conservative diving procedures. The most common areas affected are the long bones of the thigh, leg and upper arm. Occasional cases of bone cancer have developed in these lesions.

Clinical Features

When Type A lesions injure the joint, common symptoms are pain, which is usually aggravated by movement, in the affected joint and accompanied by a restriction of joint movement. As the condition progresses, severe osteoarthritis develops and the joint may eventually become frozen and incapacitating, due to pain.

Investigations

The lesions can also be identified in excellent detail, using MRI (Magnetic Resonance Imaging) scanning within days of the incident (but some of these may disappear). This is expensive but has no associated risks of irradiation. Early lesions can also be identified with radioactive Technetium ("bone scans"), which will bind to an osteonecrotic area and can be detected with a scanner within 2 weeks of the injury.

X-Rays have been the traditional investigative method but these will only reveal lesions once bone changes have developed. This may take months or years.

Treatment

The pain associated with movement can be reduced with an anti-inflammatory drug such as NSAIDS. Severe cases may require the fusion of a joint or its replacement with a synthetic joint made of either metal or plastic. While this procedure relieves the pain and increases mobility, a synthetic joint is never as robust as the "natural model" and its endurance is limited. Other techniques involve replacement from the divers healthy bone, or realignment of articular surfaces.

As the disease is regarded as an occupational hazard of diving, workers compensation claims may help off-set expensive medical costs.



Replacement hips may cause problems.

iously desirable. Most sensible divers should avoid dives deeper than 40 metres, avoid dives requiring decompression, not approach the no-decompression limits and ascend slowly. It is likely that the longer duration dives permitted with many dive computers, together with the increased number of dives and the ability to dive close to the edge of decompression commitment, now makes this disorder more likely for recreational divers.

As indicated, in divers who develop decompression sickness a follow-up bone scan after 2–4 weeks should detect areas of bone damage. MRI imaging can often be better used to determine the extent of the lesion.

Divers with high risk factors who develop unexplained joint pain should be assessed to exclude this condition.

Occupational divers and other divers who are at increased risk because of their diving practices may require regular routine screening assessments. Since X-ray investigations can involve worrisome exposure to radiation, their frequency must be weighed against the risk of osteonecrosis development, and so MRIs are preferred. Divers who are likely to be at risk are required to have a baseline investigation performed before they are employed. For some susceptible occupational divers, follow-up assessments at 5 year intervals are recommended.



Fig 17.3

Replacement hips may cause problems.